Continuing Medical Education

Emergencies in Otorhinolaryngology

Diagnostic Evaluation, Assessment of Urgency, and Treatment

Janina Hahn, Thomas Deitmer, Jan Löhler, Thomas Datzmann, René Lehner, Thomas K. Hoffmann

Department of Otorhinolaryngology, Head and Neck Surgery, Ulm University Hospital, Germany: Prof. Dr. med. Janina Hahn, Dr. med. René Lehner, Prof. Dr. med. Thomas K. Hoffmann

The German Society of Oto-Rhino-Laryngology, Head and Neck Surgery, Bonn, Germany: Prof. Dr. med. Thomas Deitmer

German Professional Association of Ear, Nose, and Throat Specialists, Neumünster, Germany: Prof. Dr. med. Jan Löhler

Clinic for Anesthesiology and Intensive Care, Ulm University Medical Center, Ulm, Germany: Prof. Dr. med. Thomas Datzmann

Summary

Background: Emergencies in otorhinolaryngology are common: According to a Spanish study, approximately 12% of patients in a general emergency room have symptoms relating to the ear, nose, or throat (ENT). Such situations range in severity from minimal to life-threatening and affect persons of all ages. These patients may present first to a general practitioner or to an emergency room without specialized ENT coverage. In this article, we discuss the assessment of clinical urgency based on symptoms, and the ensuing treatments.

Methods: This narrative review is based on pertinent publications retrieved by a literature search. Common and typical ENT emergencies are discussed, including the necessary diagnostic evaluation, time management, and treatment. For each clinical entity, "red flags" are defined, i.e., warning signs indicating the need for urgent, specialized care.

Results: Treatment by a specialist in otorhinolaryngology (usually surgical and in-hospital, and often as part of an interdisciplinary collaboration) is needed, in particular, for clinical entities that may be life-threatening, such as otogenic or sinugenic complications, neck abscesses, angioedema, posterior epistaxis, tumor hemorrhages, and foreign bodies in the respiratory tract, as well as inner ear diseases that cause severe vertigo and vomiting.

Conclusion: The rising number of patients presenting to emergency rooms presents a challenge to all affected areas of the health care system. The physician in the emergency room has the task of recognizing the risk of serious complications in certain clinical situations with nonspecific symptoms that may seem harmless, and of obtaining specialized care for these patients in a timely manner. The "red flags" presented in this article can serve as an initial guide to ENT emergencies.

Cite this as:
Hahn J, Deitmer T, Löhler J, Datzmann T, Lehner R, Hoffmann TK: Emergencies in otorhinolaryngology: Diagnostic evaluation, assessment of urgency, and treatment. Dtsch Arztebl Int 2025; 122: 533–40.
DOI: 10.3238/arztebl.m2025.0122

Emergency diagnoses in the ear, nose, and throat (ENT) area affect patients of all ages; their incidences are age-specific and seasonally variable (1–3). Upper respiratory tract infections are among the more common diagnoses in emergency rooms, especially in children (4). Out of more than 500 000 patients seen in a general emergency department in Spain, 12% had problems of the ear, nose, and throat (5).

Certain ENT disease entities require multidisciplinary assessment and interdisciplinary cooperation: the differential diagnosis of vertigo includes central nervous and cardiovascular disorders, among others; trauma in the ENT area overlaps with the areas for which ophthalmologists and oral/maxillofacial surgeons are responsible; and often, when the patient is a child, collaboration with pediatricians is advisable. In this article, we focus on common and typical ENT emergency findings and the proper timing of their diagnostic evaluation and treatment. Some of the diagnostic and therapeutic measures that will be discussed require special ENT instrumentation (e.g., speculum and bipolar cautery for epistaxis) but are still listed in the article for the sake of completeness.

Special mention is made of disease-specific red flags, i.e., symptoms and signs that imply a potentially complicated course and indicate urgent consultation with an otolaryngologist. These are summarized in *Figure 1* in relation to typical ENT emergencies, focusing on clinical manifestations and diagnoses. Risk factors such as general immunosuppression or onset in a child

Information on CME

This article has been certified by the North Rhine Academy for Continuing Medical Education. **The questions on this article may be found (in German) at http://daebl.de/RY95** (Deutsches Ärzteblatt's CME portal). **Their English translation may be found in the PDF version of this article**. The closing date for entries is September 18, 2026
Participation is possible at cme.aerztebatt.de

Figure 1

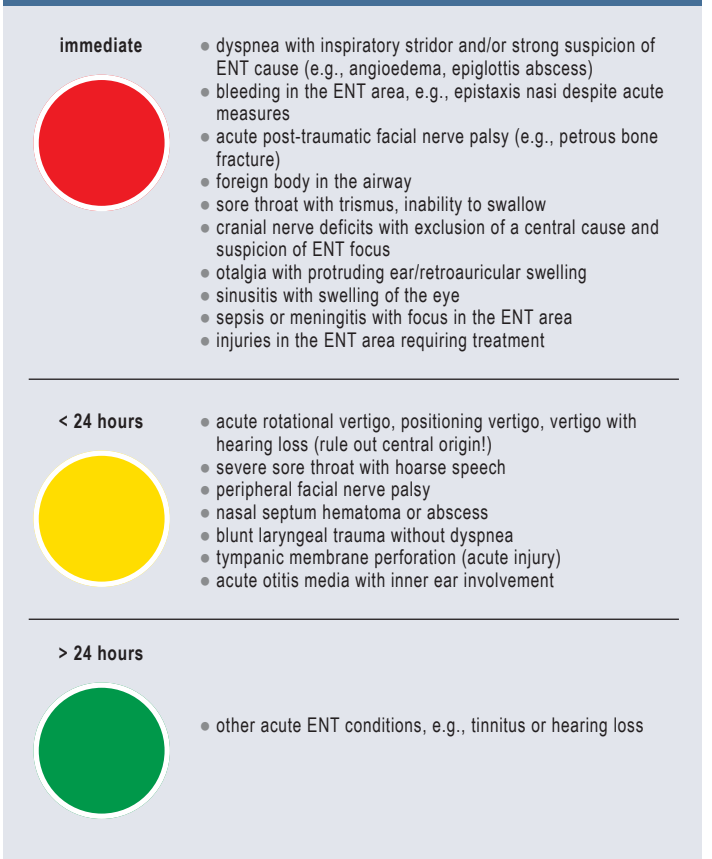

Indications for ENT consultation according to clinical manifestations or suspected diagnosis

under age 2 are not listed separately in the article and are to be considered on a case-by-case basis. Opportunities for interdisciplinary cooperation in severe and complex clinical situations (e.g., midface fractures) largely depend on the physical and personnel infrastructure of the particular health care institution, so the recommendations made here cannot be considered universally applicable.

Ten common clinical situations or symptom complexes are presented. For each of them, information is given on incidence, typical findings, and key symptoms to be determined by medical history-taking, followed by a presentation of the essential steps in diagnostic evaluation and ENT treatment, and, lastly, the pertinent disease-specific red flags.

Learning objectives

This article is intended to enable readers to:

- recognize the urgency of common emergency situations relating to the ear, nose, and throat from their typical warning manifestations;
- state the basic treatment measures for the most common ENT emergencies;
- know the basic diagnostic tests for distinguishing, e.g., a central from a peripheral vestibular cause for vertigo.

Methods

This narrative review is based on pertinent publications in English and German that were retrieved by a search in the PubMed database, with particular attention to controlled studies, guidelines, and reviews. The treatment recommendations given here have generally been formulated on the basis of information from more recent publications (from 2010 onwards); in a few cases, and for information on incidences, older publications had to be consulted as well. The contents of the ten symptom complexes were compiled by the authors, taking various aspects into account. Their order in the text is not meant to imply relative frequency or clinical importance. The main reasons for the inclusion of each topic in this article were its incidence as an emergency presentation and its relevance as a matter requiring interdisciplinary attention.

The red flags were compiled by the authors on the basis of published findings and their own clinical experience (class IV evidence in the scheme of the Agency for Healthcare Research and Quality [AHCPR]). The presence of a red flag signifies an emergency that necessitates referral to a specialist. The urgency of referral varies among red flags, as shown in detail in *Figure 1* and in the *Table*. The literature on individual ENT conditions generally does not contain any clear quantitative recommendation concerning the time frame for consultation of an otorhinolaryngologist. The time frames given in the *Table* are based not only on the available information in scientific publications and guidelines, but also on the degree of risk associated with each condition and the authors' subjective experience.

Otitis

General considerations

Cerumen obturans, otitis externa, and otitis media are among the five most common ENT emergency diagnoses (1). Their main symptoms are otalgia, otorrhea, dizziness, hearing loss, and/or tinnitus. The medical history, considered in isolation, has a no more than moderate predictive correlation with the correct diagnosis (6, 7). The Weber and Rinne tuning fork tests are helpful in the emergency diagnostic examination for distinguishing conductive from sensorineural hearing loss (6):

- Weber test: The tuning fork (e.g., 440 Hz) is struck, and its handle is held to the patient's head in the midline. The patient is asked to state where the sound is heard (in the midline or to the right or left side). The evaluation is carried out in conjunction with medical history-taking and otoscopic examination of the tympanic membrane. Lateralization to the left side (e.g.) implies either right sensorineural or left conductive hearing loss. Hearing the sound in the midline implies normal auditory function or an equal degree of hearing loss (either sensorineural or conductive) on the two sides.
- Rinne test: This is a supplement to the Weber test that is used to distinguish conductive from sensorineural hearing loss. The tuning fork is struck and held in front of one ear. After a few seconds, the handle of the tuning fork is held to the mastoid bone on the same side. The patient is asked to state which sound was louder. A louder sound with bone conduction than with air conduction implies conductive hearing loss on that side.

Table

Timing considerations in common EMT emergencies and their diagnostic evaluation

Emergency manifestations / diagnosis	Urgency of ENT consultation	Remarks on clinical course	References
Acute otitis media with inner ear involvement	within 24 hours	risk of permanent hearing damage; with early treatment (tympanostomy, antibiotics, steroids) complete restitutio ad integrum	(e28, e29)
Acute mastoiditis	immediately	risk of extension to the skull base or meninges	(e30, e31)
Sinus-related orbital complication	immediately	risk of vision loss and intracranial complications; ophthalmological evaluation required	(e32), currently under revision
Acute pharyngitis/tonsillitis	within 24 to 48 hours if severe (red flags)	risk of abscess formation	(25)
Peritonsillar/retrotonsillar/ parapharyngeal abscess	immediately	risk of airway obstruction, mediastinitis, sepsis, jugular vein thrombosis, and other complications	(25, e33)
Acute laryngitis	immediately only if there is dyspnea or stridor	laryngoscopy if necessary to rule out differential diagnoses	(27, e34)
Acute epiglottitis/ epiglottal abscess	immediately	lethal airway obstruction possible	(31, 34, 35)
Acute angioedema in the swallowing and respiratory tracts	immediately	lethal airway obstruction possible	(e35)
Acute hearing loss ± tinnitus	within ca. 7 days	tone audiometry, exclusion of differential diagnoses	(e36)
Acute vestibular vertigo	within 24 to 48 hours depending on general condition; immediate (neurological) examination in the presence of red flags	differential diagnostic evaluation for central vs. peripheral etiology is necessary	(e10, e37)
Foreign body in the ear canal	within 3 days, exception: metallic sweat bead—immediately	risk of infection, less frequently eardrum injuries	(e18, e38, e39)
Foreign body in the nose	immediately	risk of aspiration	(e19, e40)
Acute tympanic membrane perforation	within 24 to 48 hours	eardrum splinting possible	(e41, e20, e21)
Nasal trauma	depending on trauma and findings within 7 days at most; immediately in case of red flags	evaluation for septal hematoma (mean interval from trauma to diagnosis ca. 8 days); repositioning, if needed, within 14 days	(e22, e42)

Diffuse otitis externa

Diffuse otitis externa is more common in the summer, e.g., after a beach vacation (2). Typical symptoms include otorrhea, otalgia, and pain inducible by pressing on the tragus or pulling on the auricle (8). On otoscopy, the ear canal is often swollen and blocked with secretions, and there is often conductive hearing loss (9).

Diffuse otitis externa is treated by topically applied medication, e.g., in the form of ear drops or ointment strips. Antiseptic, antibiotic (e.g., ciprofloxacin), steroid, and/or antifungal (e.g., ciclopirox) preparations are used. If possible, a swab should be taken beforehand for diagnostic purposes, and the ear canal should be cleaned. The ear must also be kept dry. Pain is managed by the WHO pain ladder approach (9).

Worsening symptoms despite topical treatment, fever, and extension to the surrounding soft tissue are red flags. Pseudomastoiditis can manifest as retroauricular lymph node swelling. In such cases, the eardrum must be meticulously inspected to rule out otitis media. Older patients with diabetes mellitus may have malignant otitis externa, especially if *Pseudomonas* is detected. Cranial nerve deficits may also be present in this situation (9).

Acute otitis media

Acute otitis media is more common in the winter (2). In children (particularly younger children), it is often associated with enlarged adenoids (10). Typical symptoms are otalgia and conductive hearing loss; otorrhea is present only if the eardrum is perforated. Otoscopy reveals a reddened eardrum *(Figure 2a)*. According to an American study, 60% of children suffer from acute otitis media at least once before their third birthday (11). Globally, the incidence rate is 10.9%, according to data from 15 of the 21 WHO regions (12).

The treatment primarily consists of pain management by the WHO pain ladder approach (6, 13). Xylometazoline nose drops are often given as well (for up to 7 days, according to the product information), although clinical studies and systematic reviews have cast doubt on their utility. Systemic antibiotic therapy is indicated in case of marked or worsening symptoms and signs, or risk factors such as fever above 39°C, immune compromise, or age under 2 years. Antibiotic treatment should be considered on a case-to-case basis; it must be recalled that uncomplicated cases without risk factors often heal spontaneously within two days. A follow-up examination in 2–3 days is generally recommended. The antibiotic of choice is amoxicillin (50–60 mg/kg body weight per day, divided into three doses).

Red flags include sensorineural in addition to conductive hearing loss (detectable with a tuning fork test), vertigo, swelling or redness above the mastoid process, possibly with protruding ear *(Figure 2b)*,

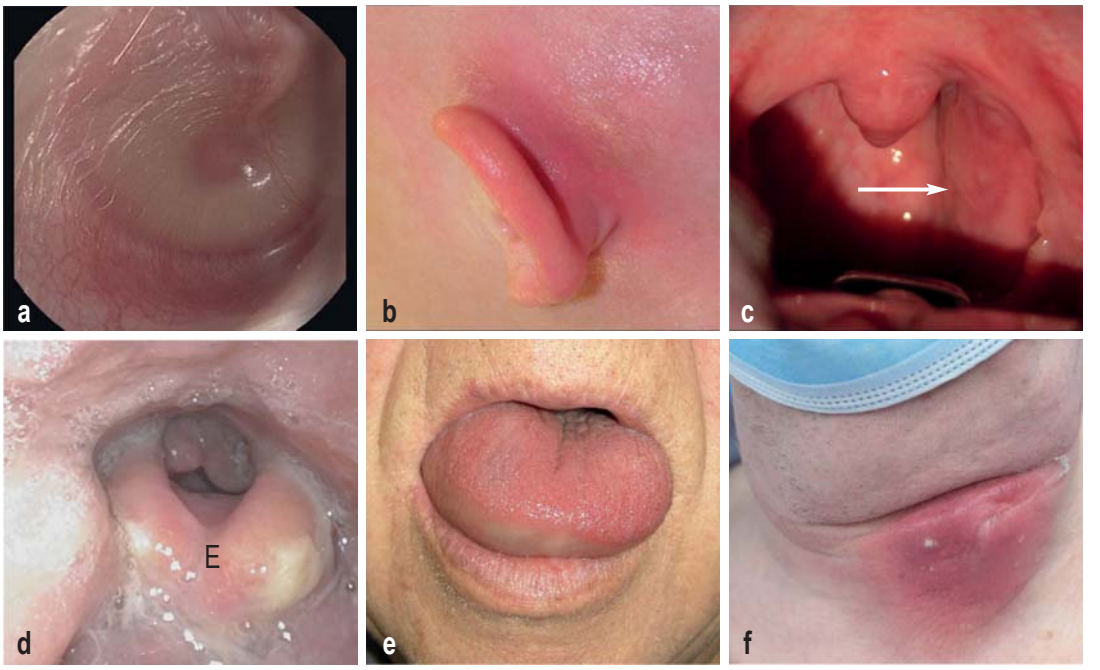

Figure 2: Examples of common findings in ENT emergencies
a) Otomicroscopy: dull, reddened right tympanic membrane: acute serous otitis media
b) left ear, posterior aspect: acute mastoiditis
c) left retrotonsillar abscess
d) flexible laryngoscopy, 0° optics: the epiglottis (E) is swollen and coated; epiglottal abscess
e) acute angioedema of the tongue
f) left cervial abscess

progression under antibiotic treatment, facial palsy, and clinical signs of meningitis.

Acute (rhino-)sinusitis

Acute (rhino-)sinusitis is usually of viral origin (14) and mainly occurs in the winter (2). Typical symptoms are rhinorrhea, nasal obstruction, hyposmia or anosmia, and headaches, which may worsen when the patient bends forward. Fever may be present as well. The one-year prevalence is 6–15% (15). The treatment is with analgesics according to the WHO guidelines and xylometazoline nose drops over the short term. Antibiotics should only be given for strict indications according to the EPOS 2020 criteria, which require at least three of the following: fever above 38°C, worsening symptoms after initial improvement, unilateral symptoms, severe pain, or elevated inflammatory values. Amoxicillin and penicillin are the antibiotics of choice (15).

Red flags include signs of orbital involvement, such as swelling around the eye, diplopia, other ophthalmological or neurological symptoms, signs of meningitis, or persistent pain despite treatment.

Epistaxis

Epistaxis can be due to a systemic condition, such as the use of anticoagulant drugs, coagulation disorders, hereditary hemorrhagic telangiectasia (Osler-Weber-Rendu disease), or hypertension, or a local disturbance, such as septal perforation, manipulation in the area of Kiesselbach's plexus, or rhinitis sicca (16). It is the most common ENT emergency: some 60% of people have a nosebleed at least once in their lives, and approximately 6% require medical attention (17–19).

Epistaxis is treated by compression of the nostrils with the patient seated and leaning slightly forward. Further helpful measures include antihypertensive treatment, cooling of the neck, and avoidance of swallowing blood, both to lessen nausea and to enable more accurate estimation of the quantity of blood lost. Depending on severity, a nasal tamponade with aspiration protection or bipolar cauterization may be needed. Monitoring of the hemoglobin level is recommended (20–22).

Red flags include hemodynamically significant bleeding with a drop in hemoglobin, persistent bleeding despite tamponade, and possible blood aspiration. In such cases, surgical intervention (e.g., on the sphenopalatine artery) is often needed.

Acute (tonsillo-)pharyngitis

Tonsillitis/pharyngitis is most common in the colder months (2). Its exact incidence is difficult to determine, as it usually arises as part of a general respiratory tract infection. According to the Robert Koch Institute's RKI-GrippeWeb, approximately 5.3 million respiratory illnesses were registered in Germany in the week 7–13 April 2025, corresponding to 63 cases per 1000 inhabitants per week. Sore throats are among the 15 most common reasons for consulting a primary care physician in Germany (23).

Typical symptoms include odynophagia, dysphagia, and fever. Epstein-Barr virus tonsillitis (especially in younger patients) is also accompanied by swollen cervical lymph nodes (24). The mucous membrane is reddened and may be edematous; the tonsils may be covered with spots or coatings, reddened, and enlarged.

Treatment is carried out in accordance with the German clinical practice guideline (25), with local anesthetic measures, analgesia according to the WHO scheme, and, if necessary, antibiotics, depending on the clinical score (e.g., Centor) (26). If EBV tonsillitis is suspected, aminopenicillins should not be given, as they may produce a rash. Acetaminophen should not be given either because of its potential hepatotoxicity.

Red flags include signs of an abscess (e.g., trismus, unilateral symptoms, uvular edema or displacement), worsening despite treatment, dyspnea with tonsil hypertrophy, and severely restricted swallowing.

Laryngitis and epiglottitis

Laryngitis is the most common cause of hoarseness: acute laryngitis is the cause in 42% of all hoarse patients, and

Figure 3: Head-impulse test, eye cover test, and examination for nystagmus.
a) Head impulse test: The patient fixes gaze on the examiner's nose. The patient's head is held and suddenly turned in the horizontal plane approximately 30° from the central position, first in one direction and then in the other. A patient with acute unilateral peripheral vestibulopathy will be unable to keep the gaze fixed on the examiner's nose and will display pursuit saccades on passive turning of the head to the affected side. Abnormal findings imply the presence of a peripheral vestibulopathy.
b) Eye cover test: The patient fixes gaze on a point in the room and the examiner first covers one eye, then the other, repeating this several times, observing the uncovered eye each time. Vertical divergence should arouse suspicion of a central lesion.
c) Spontaneous nystagmus: in the nystagmus test, Frenzel glasses are used to inspect spontaneous nystagmus. Any change in the direction of spontaneous nystagmus suggests a central lesion.

chronic laryngitis in 10% (27). Acute laryngitis is usually of viral origin (28), and its symptoms can be exacerbated by smoking and other factors. Sore throat is a further symptom.

Acute epiglottitis is often accompanied by pronounced malaise, a sudden high fever, severe sore throat, and dyspnea. The patient usually prefers to sit rather than lie down. The vaccination history should be obtained, particularly with regard to *Haemophilus influenzae* type B (epiglottitis) and diphtheria ("true croup") (29).

As many as 20% of hospitalized adults with acute epiglottitis need respiratory intervention (e.g., intubation, tracheotomy) (30).

Acute, uncomplicated laryngitis is usually self-limiting. Analgesia according to the WHO scheme and inhalation therapy are recommended (27).

If acute epiglottitis or an epiglottal abscess is suspected, emergency ENT consultation with laryngoscopy is indicated. An imaging study may also be needed to define the abscess. Antibiotics are given, e.g., an aminopenicillin combined with a beta-lactamase inhibitor. Systemic steroids are frequently mentioned in the literature (30, 34), but their use is debated and not supported by clinical trials. Abscesses must be surgically drained. The airway should be managed in an interdisciplinary collaboration, including close coordination with the anesthesia department, with the provision of a video laryngoscope and, where indicated, awake fiberoptic intubation or tracheotomy. Endoscopy often demonstrates an abscess as a bulge of the reddened laryngeal mucosa containing a translucent area with purulence underneath *(Figure 2d)*.

Differential diagnoses include malignancies, foreign body aspiration, or—in children—pseudocroup (subglottal laryngitis) with barking cough and inspiratory stridor (35).

Red flags include suspected epiglottal abscess, dyspnea, low SpO_2, inspiratory stridor, slurred speech, rapid progression, and inability to swallow saliva.

Cervical abscess

Inflammation or abscess formation in the deep or subcutaneous soft tissues of the neck manifests itself with pain, skin redness, swelling *(Figure 2f)*, and, in some cases, restricted cervical mobility. Evacuation of the abscess is the goal of treatment (36). Potential sources of infection, e.g., in the teeth or tonsils, should be identified and treated if possible (37). As the cervical fascia runs vertically, there is a risk of mediastinal spread (37). Imaging is usually necessary for surgical planning, e.g., ultrasonography or computed tomography, depending on the anatomical site (38).

In the absence of specific guidelines, the treatment recommended in the pertinent literature (36, 38, 39) includes surgical decompression followed by drainage, usually for several days; initial broad-spectrum intravenous antibiotic treatment (e.g., ampicillin-sulbactam or clindamycin), adjusted thereafter on the basis of culture and sensitivity findings; and hospital admission for observation. Any focus of infection that is detected should be eradicated.

Red flags include suspected neck abscess with redness, swelling, pain, and dysphagia, especially when accompanied by torticollis, dyspnea, signs of sepsis, suspected necrotizing fasciitis, or Lemierre syndrome (fusobacteria, sepsis, thrombosis of the internal jugular vein).

Angioedema

Angioedema is not a disease in itself, but rather a symptom of an underlying condition (40). Involvement of any part of the airway, e.g., the tongue *(Figure 2e)*, is especially dangerous. Important questions to ask when taking the medical history include known allergies, recognizable triggers, signs of anaphylaxis, wheal formation, or itching, as well as medication history—especially with regard to ACE inhibitors and NSAIDs. One should also ask about any known family history of urticaria or hereditary angioedema (HAE).

Histamine- or mast cell-mediated angioedema often occurs in conjunction with urticaria, allergies, and anaphylaxis. It is often accompanied by itching and hives; in severe cases of anaphylaxis, systemic symptoms are also present. Depending on severity, the appropriate treatment includes elimination of the trigger (if possible) and the administration of systemic steroids, antihistamines, and—for

anaphylaxis—intravenous and inhaled epinephrine, and oxygen if necessary (e1, e2). Further measures are taken in accordance with the guidelines.

Bradykinin-mediated angioedema, e.g., due to HAE or treatment with ACE inhibitors, requires specific treatment. In HAE, the acute treatment is with intravenous C1 inhibitors or subcutaneous administration of the bradykinin receptor blocker icatibant (e3). There is currently no approved treatment for ACE-inhibitor–induced angioedema; there have been a few case reports of the off-label use of the same treatments given for HAE (e4).

It is important to note that manipulating the area affected by angioedema can make the symptoms worse. Interdisciplinary airway management may be needed.

Red flags include dyspnea, a drop in oxygen saturation, inspiratory stridor, sialorrhea, slurred speech, and rapid progression.

Acute hearing loss, tinnitus, and vertigo

The term "sudden hearing loss" refers to acute, spontaneous, usually unilateral hearing loss originating in the inner ear, with or without tinnitus, but without otalgia. Otoscopy and the Weber and Rinne tuning fork tests are the main examination modalities for emergency diagnosis. The incidence of sudden hearing loss in Germany is ca. 300 per 100 000 people per year (e5). Tinnitus is one of the five most common reasons for emergency ENT consultation (1).

The treatment of sudden hearing loss presented here is modified from the recommendations of Reference (e6). No drug has been clearly shown to be effective; spontaneous remission is common, and there are insufficient data from clinical trials. Recommended measures include avoiding noise and, in many publications, treatment with systemic or intratympanic steroids, mostly off-label (e7, e8). The benefit of steroids remains unclear, as controlled trials have yielded conflicting results—perhaps because they have mainly been on a small scale (e9). The pertinent German clinical practice guideline is currently being revised.

Information on vertigo as an ENT emergency is found in References (e10) and (e11). The lifetime prevalence of rotational or swaying vertigo is approximately 30% (e12). There are three main differential diagnoses of vertigo with a peripheral vestibular origin: benign paroxysmal positional vertigo (BPPV), acute unilateral vestibulopathy, and Menière's disease. The duration and precipitating factors of vertigo are different for each disease entity; so-called HINTS testing (head-impulse test, nystagmus test, and eye cover [skew] test) is helpful for differentiating central and peripheral causes *(Figure 3)*. Age, pre-existing conditions, and long-term medication should be considered in the assessment. Vertigo of central origin may require immediate intervention.

The treatment depends on the specific diagnosis. Physical training is recommended: positioning exercises for BPLS, balance exercises for vestibulopathy. Antiemetic drugs and fluid replacement may be needed in the acute phase. Vestibulopathy is often treated with systemic steroids (e13). In cases of severe symptoms with emesis or risk of falling, hospital admission may be necessary.

Red flags include additional neurological symptoms and abnormal findings on HINTS testing, e.g., change in direction of nystagmus, vertical nystagmus, or an abnormal eye cover test. Any such finding is an indication for immediate neurological evaluation.

Tumors

Malignant tumors in the larynx and pharynx in particular can cause airway obstruction and dyspnea, as can bleeding in the airway (e14).

The proper treatment steps are presented in the S1 guideline on airway management (e15). Depending on the findings, early interdisciplinary airway management may be needed (e.g., intubation in readiness for tracheotomy, video laryngoscopy). In the event of bleeding and an existing tracheostoma, a blockable tracheal cannula with manometric control should be used to block the trachea securely and prevent aspiration. If possible, the source of bleeding should be compressed. Tranexamic acid can also be administered locally and/or intravenously (e16, e17).

Red flags include dyspnea, low SpO_2, inspiratory stridor, sialorrhea, slurred speech, and bleeding from a tumor in the oral cavity, pharynx, or larynx.

Trauma and foreign bodies

Foreign bodies in the ear canal are seen mainly in young children. Their removal is not usually urgent, as there is no risk of dislocation if the eardrum is intact. To avoid injury or inflammation, removal should be performed within a few days under otomicroscopic control (e18).

Foreign bodies in the nose are also common in young children. Because of the risk of displacement into the airways, these should be removed as soon as possible—not with forceps, but with a hook, under anterior rhinoscopy (e19).

The eardrum can be perforated by cotton swabs, blast trauma, or a blow to the ear. An immediate visit to an ENT specialist is recommended. If the wound edges are fresh, splinting of the eardrum can be considered, e.g., with silicone film (e20). Small perforations usually heal spontaneously (e21).

In case of nasal trauma with a new deviation of the bony nose, prompt ENT examination is necessary. The nose should be repositioned within 14 days if possible (e22). Conventional x-rays are obsolete in this setting; CT may be needed if a midface fracture is suspected (e23, e24).

Red flags include signs of a septal hematoma or septal abscess, worsening nasal breathing difficulty, worsening pain several days after the injury, and a ballooned nasal septum. In such cases, rapid surgical decompression is indicated; abscesses must be treated with antibiotics as well.

General challenges and future perspectives

The total number of ENT emergencies in Germany is on the rise: In a press release (No. N061) dated 9 December 2024, the Federal Statistical Office (Destatis) announced that 12.4 million outpatient ENT emergencies were treated in German hospitals in 2023, which is the highest figure since record-keeping began in 2018.

Over the period 2009–2019, the total number of emergency patients treated by the on-call service of the Association of Statutory Health Insurance Physicians

and in hospital emergency rooms in Germany rose from 24.9 to 27.8 million (e25), while the number of emergency patients in hospitals rose from 14.9 to 19.1 million. Emergency patients often turn directly to university hospital and other general hospital outpatient clinics without consulting any other physician (e26).

In view of the ongoing centralization of emergency care structures in Germany, there will be a need for suitable instruments for the initial assessment and triage of ENT emergencies. This article is intended to provide guidance for the recognition of critical situations of this type. The use of artificial intelligence and digitally controlled triage systems (e27) is likely to be discussed in the future as well. Physicians will continue to face the challenge of timely recognition of cases of impending danger among the multitude of seemingly ordinary cases with nonspecific symptom combinations, and their prompt referral for the necessary specialized care.

Conflict of interest statement
The authors state that no conflict of interest exists.

Manuscript received on 7 February 2025; revised version accepted on 27 June 2025.

Translated from the original German by Ethan Taub, M.D.

References (abbreviated)

1. Ahmad Z, et al.: HNO 2023; 71 (Suppl 1): 67–72.
2. Kaur R, et al.: Pediatrics 2017; 140: e20170101.
3. Monasta L, et al.: PLoS One 2012; 7: e36226.
4. El Feghaly RE et al.: Expert Rev Anti Infect Ther 2023; 21: 523–34.
5. Jaume F, et al.: Curr Allergy Asthma Rep 2020; 20: 28.
6. Fokkens WJ, et al.: Rhinology 2020; 58: 82–111.
7. Breyer N, et al.: Laryngorhinootologie 2025; 104: 371–8.
8. Kuhr E, et al.: Laryngorhinootologie 2019; 98: 625–30.
9. Lochbaum R, et al.: HNO 2022; 70: 601–8.
10. Hadar A, et al.: Ear Nose Throat J 2023; 1455613231189056.
11. Yoong SYC, et al.: BMC Pediatr 2021; 21: 172.
12. Merino-Galvez E, et al.: Eur Arch Otorhinolaryngol 2019; 276: 911–7.
13. Thomas JP, et al.: Dtsch Arztebl Int 2014; 111: 151–60.
14. Coker TR, et al.: JAMA 2010; 304: 2161–9.
15. Jackson EA, Geer K: Am Fam Physician 2023; 107: 145–51.
16. Wiegand S, et al.: Dtsch Arztebl Int 2019; 116: 224–34.
17. Ruhela S, et al.: Indian J Otolaryngol Head Neck Surg 2023; 75 (Suppl 1): 828–35.
18. Petruson B, Rudin R: Rhinology 1975; 13: 129–33.
19. Small M, et al.: Health Bull (Raleigh) 1982; 40: 20–9.
20. Tunkel DE, et al.: Otolaryngol Head Neck Surg 2020; 162 (1_Suppl): 1–38.
21. Morgan DJ, et al.: Prim Care 2014; 41: 63–73.
22. Beck R, et al.: Dtsch Arztebl Int 2018; 115: 12–22.
23. Schaefert R, et al.: Urban und Vogel 2010. 67–75.
24. Balfour HHJ, et al.: Clin Transl Immunol 2015; 4: e33.
25. www.iqwig.de/projekte/v21–09.html.
26. Centor RM, et al.: Med Decis Making 1981; 1: 239–46.
27. Reiter R, et al.: Dtsch Arztebl Int 2015; 112: 329–37.
28. Reveiz L, et al.: Cochrane Database Syst Rev 2015; 2015: CD004783.
29. Mazurek H, et al.: Adv Respir Med 2019; 87: 308–16.
30. Guardiani E, et al.: Laryngoscope 2010; 120: 2183–8.
31. Sutton AE, Guerra AM, Waseem M: Epiglottitis. [Updated 2024 Oct 5].
32. https://register.awmf.org/de/leitlinien/detail/017–066
33. https://register.awmf.org/de/leitlinien/detail/053–010
34. Navaratnam AV, et al.: Br J Gen Pract 2015; 65: 99–100.
35. Dowdy RAE: Anesth Prog 2020; 67: 90–7.
36. Gehrke T, et al.: Eur Arch Otorhinolaryngol 2022; 279: 1585–92.
37. Huang TT, et al.: Head Neck 2004; 26: 854–60.
38. Osborn TM, et al.: Oral Maxillofac Surg Clin North Am 2008; 20: 353–65.
39. Celakovsky P, et al.: Eur Arch Otorhinolaryngol 2014; 271: 1679–83.
40. Hahn J, et al.: Dtsch Arztebl Int 2017; 114: 489–96.

Corresponding author
Prof. Dr. med. Janina Hahn
Janina.Hahn@uniklinik-ulm.de

Supplementary material
Complete list of full references and eReferences:
www.aerzteblatt-international.de/m2025.0122

Further information on CME

- The completion time for all newly started CME units is 12 months. The results can be accessed 4 weeks following the start of the CME unit.
- CME points can be managed using the “uniform CME number” (einheitliche Fortbildungsnummer, EFN). The EFN must be stated during registration on www.aerzteblatt.de (“Mein DÄ”) or entered in “Meine Daten,” and consent must be given for results to be communicated. The 15-digit EFN can be found on the CME card (8027XXXXXXXXXXX).

Questions on this article

Participation is possible at cme.aerzteblatt.de. The submission deadline is 18 September 2026

Only one answer is possible per question. Please select the answer that is most appropriate.

Question 1

Which of the following measures is approapriate in the treatment of diffuse otitis externa?

a) systemic antibiotics as first-line therapy
b) use of nose drops containing xylometazoline
c) keeping the affected ear dry
d) intravenous steroids
e) immediate tympanic drainage

Question 2

Which of the following manifestations is typical of acute otitis media?

a) dizziness
b) otorrhea with intact eardrum
c) conductive hearing loss
d) pain induced by pressure on the tragus
e) pain induced by pulling on the auricle

Question 3

What criterion justifies the administration of antibiotics for acute rhinosinusitis, according to the 2020 EPOS guideline?

a) bilateral symptoms
b) fever above 38 °C
c) vertigo
d) hyposmia without fever
e) anosmia without fever

Question 4

What should be avoided in the treatment of acute epistaxis?

a) compression of the nostrils
b) local cooling of the neck
c) swallowing blood
d) administration of antihypertensive drugs
e) nasal tamponade with aspiration protection

Question 5

Which of the following measures should not be performed if EBV tonsillitis is suspected?

a) administration of paracetamol
b) local anesthetic measures
c) administration of antibiotics according to the Centor score
d) analgesia according to the WHO scheme
e) smear test

Question 6

Which of the following manifestations is a red flag in acute epiglottitis?

a) hoarseness
b) inspiratory stridor
c) fever below 38 °C
d) sore throat without dyspnea
e) headache

Question 7

Which of the following drug classes most commonly causes non-allergic angioedema of the head and neck area as a side effect?

a) antihistamines
b) ACE inhibitors
c) AT1 receptor antagonists
d) corticosteroids
e) bradykinin receptor blockers

Question 8

Which of the following measures is indicated as an acute measure for bradykinin-mediated hereditary angioedema?

a) administration of antihistamines
b) intravenous administration of C1 inhibitors
c) administration of epinephrine
d) local cooling
e) systemic steroid administration

Question 9

What diagnostic technique helps to distinguish central from peripheral vertigo?

a) nasopharyngoscopy
b) head impulse test
c) cotton test
d) sonography of the mastoid
e) serum analysis of C1-INH

Question 10

Which of the following measures is indicated for a septal hematoma?

a) tranexamic acid p.o.
b) prompt surgical decompression
c) x-ray of the nasal pyramid
d) heat application
e) radiofrequency reduction of the turbinates

Participation only via the internet: cme.aerzteblatt.de

Supplementary material to accompany the article

Emergencies in Otorhinolaryngology

Diagnostic Evaluation, Assessment of Urgency, and Treatment

by Janina Hahn, Thomas Deitmer, Jan Löhler, Thomas Datzmann, René Lehner, and Thomas Karl Hoffmann

Dtsch Arztebl Int 2025; 122: 533–40. DOI: 10.3238/arztebl.m2025.0122

Complete list of full references

1. Kuhr E, Werner JA, Dietz A, Wiegand S: [Analysis of the emergency patients of a university ENT hospital]. Laryngorhinootologie 2019; 98: 625–30.
2. Lochbaum R, Tewes S, Hoffmann TK, Greve J, Hahn J: [Typical emergencies in otorhinolaryngology—A monocentric analysis of the seasonal course]. HNO 2022; 70: 601–8.
3. Hadar A, Shaul C, Ghantous J, et al.: Risk factors for severe clinical course in epistaxis patients. Ear Nose Throat J 2023; 1455613231189056.
4. Yoong SYC, Ang PH, Chong SL, et al.: Common diagnoses among pediatric attendances at emergency departments. BMC Pediatr 2021; 21: 172.
5. Merino-Galvez E, Gomez-Hervas J, Perez-Mestre D, Llamas-Peiro JM, Perez-Gil E, Belda-Palazon M: Epidemiology of otorhinolaryngologic emergencies in a secondary hospital: Analysis of 64,054 cases. Eur Arch Otorhinolaryngol 2019; 276: 911–7.
6. Thomas JP, Berner R, Zahnert T, Dazert S: Acute otitis media: A structured approach. Dtsch Arztebl Int 2014; 111: 151–60.
7. Coker TR, Chan LS, Newberry SJ, et al.: Diagnosis, microbial epidemiology, and antibiotic treatment of acute otitis media in children: A systematic review. JAMA 2010; 304: 2161–9.
8. Jackson EA, Geer K: Acute otitis externa: Rapid evidence review. Am Fam Physician 2023; 107: 145–51.
9. Wiegand S, Berner R, Schneider A, Lundershausen E, Dietz A: Otitis externa—investigation and evidence-based treatment. Dtsch Arztebl Int 2019; 116: 224–34.
10. Ahmad Z, Krüger K, Lautermann J, et al.: Adenoid hypertrophy-diagnosis and treatment: The new S2k guideline. HNO 2023; 71 (Suppl 1): 67–72.
11. Kaur R, Morris M, Pichichero ME: Epidemiology of acute otitis media in the postpneumococcal conjugate vaccine era. Pediatrics 2017; 140: e20170101.
12. Monasta L, Ronfani L, Marchetti F, et al.: Burden of disease caused by otitis media: Systematic review and global estimates. PLoS One 2012; 7: e36226.
13. El Feghaly RE, Nedved A, Katz SE, Frost HM: New insights into the treatment of acute otitis media. Expert Rev Anti Infect Ther 2023; 21: 523–34.
14. Jaume F, Valls-Mateus M, Mullol J: Common cold and acute rhinosinusitis: Up-to-date management in 2020. Curr Allergy Asthma Rep 2020; 20: 28.
15. Fokkens WJ, Lund VJ, Hopkins C, et al.: Executive summary of EPOS 2020 including integrated care pathways. Rhinology 2020; 58: 82–111.
16. Breyer N, Mayer B, Lindemann J, Hoffmann TK, Hahn J: [Nasal hemorrhage—risk factors and management in 707 outpatient and inpatient patients]. Laryngorhinootologie 2025; 104: 371–8.
17. Ruhela S, Mittal HK, Bist SS, Luthra M, Kumar L, Agarwal VK: Clinico-etiological evaluation of epistaxis. Indian J Otolaryngol Head Neck Surg 2023; 75 (Suppl 1): 828–35.
18. Petruson B, Rudin R: The frequency of epistaxis in a male population sample. Rhinology 1975; 13: 129–33.
19. Small M, Murray JA, Maran AG: A study of patients with epistaxis requiring admission to hospital. Health Bull (Raleigh) 1982; 40: 20–9.
20. Tunkel DE, Anne S, Payne SC, et al.: Clinical practice guideline: Nosebleed (Epistaxis). Otolaryngol Head Neck Surg 2020; 162 (1_suppl): S1–S38.
21. Morgan DJ, Kellerman R: Epistaxis: Evaluation and treatment. Prim Care 2014; 41: 63–73.
22. Beck R, Sorge M, Schneider A, Dietz A: Current approaches to epistaxis treatment in primary and secondary care. Dtsch Arztebl Int 2018; 115: 12–22.
23. Schaefert R, Kaufmann C, Bölter R, Herzog W: Hausärztliche Diagnosevergabe bei funktionellen/somatoformen Beschwerden. Versorgungsforschung in der Hausarztpraxis Ergebnisse aus dem CONTENT-Projekt 2006–2009. 2010. 67–75.
24. Balfour HHJ, Dunmire SK, Hogquist KA: Infectious mononucleosis. Clin Transl Immunol 2015; 4: e33.
25. Deutsche Gesellschaft für Hals-Nasen-Ohren-Heilkunde K und HC: S3-Leitlinie (Langfassung) Therapie der Tonsillo-Pharyngitis – AWMF-Register-Nr. 017/024. (017). Available from: www.iqwig.de/projekte/v21–09.html.
26. Centor RM, Witherspoon JM, Dalton HP, Brody CE, Link K: The diagnosis of strep throat in adults in the emergency room. Med Decis Making 1981; 1: 239–46.
27. Reiter R, Hoffmann TK, Pickhard A, Brosch S: Hoarseness—causes and treatments. Dtsch Arztebl Int 2015; 112: 329–37.
28. Reveiz L, Cardona AF: Antibiotics for acute laryngitis in adults. Cochrane Database Syst Rev 2015; 2015: CD004783.
29. Mazurek H, Bręborowicz A, Doniec Z, et al.: Acute subglottic laryngitis. Etiology, epidemiology, pathogenesis and clinical picture. Adv Respir Med 2019; 87: 308–16.
30. Guardiani E, Bliss M, Harley E: Supraglottitis in the era following widespread immunization against Haemophilus influenzae type B: Evolving principles in diagnosis and management. Laryngoscope 2010; 120: 2183–8.
31. Sutton AE, Guerra AM, Waseem M: Epiglottitis. [Updated 2024 Oct 5]. In: StatPearls [Internet]. Treasure Island (FL): StatPearls Publishing; 2025 Jan.
32. Deutsche Gesellschaft für Hals-Nasen-Ohren-Heilkunde, Kopf- und Hals-Chirurgie e. V.: S2K-Leitlinie: Antibiotikatherapie bei HNO-Infektionen. https://register.awmf.org/de/leitlinien/detail/017–066 (last accessed on 27 August 2025).
33. Oltrogge JH (DEGAM), Chenot JF (DEGAM), Schmiemann G (DEGAM), et al.: S3-Leitlinie Halsschmerzen 2020. https://register.awmf.org/de/leitlinien/detail/053–010 (last accessed on 27 August 2025).
34. Navaratnam AV, Smith ME, Majeed A, McFerran DJ: Adult supraglottitis: A potential airway emergency that can present in primary care. Br J Gen Pract 2015; 65: 99–100.
35. Dowdy RAE, Cornelius BW: Medical management of epiglottitis. Anesth Prog 2020; 67: 90–7.
36. Gehrke T, Scherzad A, Hagen R, Hackenberg S: Deep neck infections with and without mediastinal involvement: Treatment and outcome in 218 patients. Eur Arch Otorhinolaryngol 2022; 279: 1585–92.
37. Huang TT, Liu TC, Chen PR, Tseng FY, Yeh TH, Chen YS: Deep neck infection: Analysis of 185 cases. Head Neck 2004; 26: 854–60.
38. Osborn TM, Assael LA, Bell RB: Deep space neck infection: Principles of surgical management. Oral Maxillofac Surg Clin North Am 2008; 20: 353–65.
39. Celakovsky P, Kalfert D, Tucek L, et al.: Deep neck infections: Risk factors for mediastinal extension. Eur Arch Otorhinolaryngol 2014; 271: 1679–83.
40. Hahn J, Hoffmann TK, Bock B, Nordmann-Kleiner M, Trainotti S, Greve: Angioedema—an interdisciplinary emergency. Dtsch Arztebl Int 2017; 114: 489–96.

Additional references (eReferences)

e1. Muraro A, Worm M, Alviani C, et al.: EAACI guidelines: Anaphylaxis (2021 update). Allergy 2022; 77: 357–77.

e2. Zuberbier T, Abdul Latiff AH, Abuzakouk M, et al.: The international EAACI/GA²LEN/EuroGuiDerm/APAAACI guideline for the definition, classification, diagnosis, and management of urticaria. Allergy 2022; 77: 734–66.

e3. Maurer M, Magerl M, Betschel S, et al.: The international WAO/EAACI guideline for the management of hereditary angioedema—the 2021 revision and update. Allergy 2022; 77: 1961–90.

e4. Baş M, Greve J, Stelter K, et al.: A randomized trial of icatibant in ACE-inhibitor-induced angioedema. N Engl J Med 2015; 372: 418–25.

e5. Suckfüll M: Perspectives on the pathophysiology and treatment of sudden idiopathic sensorineural hearing loss. Dtsch Arztebl Int 2009; 106: 669–75.

e6. Marx M, Younes E, Chandrasekhar SS, et al.: International consensus (ICON) on treatment of sudden sensorineural hearing loss. Eur Ann Otorhinolaryngol Head Neck Dis 2018; 135 (1S): S23–S8.

e7. Plontke SK, Meisner C, Agrawal S, et al.: Intratympanic corticosteroids for sudden sensorineural hearing loss. Cochrane database Syst Rev 2022; 7: CD008080.

e8. Plontke SK: The HODOKORT trial and current aspects of treatment of idiopathic sudden sensorineural hearing loss with glucocorticoids. HNO 2024; 72: 389–92.

e9. Wei BPC, Stathopoulos D, O'Leary S: Steroids for idiopathic sudden sensorineural hearing loss. Cochrane database Syst Rev 2013; 2013: CD003998.

e10. Brandt T, von Breveren M, Dieterich M, et al.: S2k-Leitlinie „Vestibuläre Funktionsstörungen". https://register.awmf.org/assets/guidelines/017–078l_S2k_Vestibulaere-Funktionsstoerungen_2021–05.pdf (last accessed on 27 August 2025).

e11. Strupp M, Dieterich M, Brandt T: The treatment and natural course of peripheral and central vertigo. Dtsch Arztebl Int 2013; 110: 505–6.

e12. Neuhauser HK: Epidemiology of vertigo. Curr Opin Neurol 2007; 20: 40–6.

e13. Strupp M, Bisdorff A, Furman J, et al.: Acute unilateral vestibulopathy/vestibular neuritis: Diagnostic criteria. J Vestib Res 2022; 32: 389–406.

e14. Riekert M, Rempel V, Keilwerth S, Zöller JE, Kreppel M, Schick VC: Airway-associated complications with and without primary tracheotomy in oral squamous cell carcinoma surgery. J Craniofac Surg 2023; 34: 279–83.

e15. Piepho T, Kriege M, Byhahn C, et al.: S1-Leitlinie Atemwegsmanagement 2023. Anasthesiol Intensivmed 2024; 65: 69–96.

e16. Low THH, Huang J, Reid C, Elliott M, Clark JR: Treatment of bleeding upper aerodigestive tract tumor—a novel approach with antifibrinolytic agent: Case series and literature review. Laryngoscope 2013; 123: 2449–52.

e17. Atreya S: High-dose continuous infusion of tranexamic acid for controlling life-threatening bleed in advanced cancer patients. Indian J Palliat Care 2021; 27: 172–5.

e18. Prasad N, Harley E: The aural foreign body space: A review of pediatric ear foreign bodies and a management paradigm. Int J Pediatr Otorhinolaryngol 2020; 132: 109871.

e19. Loperfido A, Mammarella F, Giorgione C, Celebrini A, Acquaviva G, Bellocchi G: Management of foreign bodies in the ear, nose and throat in pediatric patients: Real-life experience in a large tertiary hospital. Cureus 2022; 14: e30739.

e20. Zong H, Lou Z: Healing large traumatic tympanic membrane perforations using vaseline gauze and gelfoam patching alone. Ear Nose Throat J 2023; 1455613221150571.

e21. Smith M, Darrat I, Seidman M: Otologic complications of cotton swab use: One institution's experience. Laryngoscope 2012; 122: 409–11.

e22. Fattahi T, Steinberg B, Fernandes R, Mohan M, Reitter E: Repair of nasal complex fractures and the need for secondary septorhinoplasty. J Oral Maxillofac Surg 2006; 64: 1785–9.

e23. Kühnel TS, Reichert TE: Trauma of the midface. GMS Curr Top Otorhinolaryngol Head Neck Surg 2015; 14: Doc06.

e24. Hoffmann JF: An algorithm for the initial management of nasal trauma. Facial Plast Surg 2015; 31: 183–93.

e25. Regierungskommission D, Notfallversorgung D: Vorschläge zur Entlastung. 2023; 120: 323–4.

e26. Schlicht L, Guntinas-Lichius O: [The significance of the emergency department of the Jena ENT Clinic in outpatient health care]. HNO 2012; 60: 618–21.

e27. Krafft E, Kaulitz S, Voelker J, et al.: [Initial assessment of ENT emergencies—a feasibility study]. HNO 2025; 73: 111–21.

e28. Park JH, Park SJ, Kim YH, Park MH: Sensorineural hearing loss: A complication of acute otitis media in adults. Eur Arch Otorhinolaryngol 2014; 271: 1879–84.

e29. Li G, Li T, Liu H, Sun L: Correlation between recovery time of extended high-frequency audiometry and duration of inflammation in patients with acute otitis media. Eur Arch Otorhinolaryngol 2020; 277: 2447–53.

e30. Palma S, Bovo R, Benatti A, et al.: Mastoiditis in adults: A 19-year retrospective study. Eur Arch Otorhinolaryngol 2014; 271: 925–31.

e31. Cassano P, Ciprandi G, Passali D: Acute mastoiditis in children. Acta Biomed 2020; 91: 54–9.

e32. DGHNO-KHC/DEGAM: S2k-Leitlinie Rhinosinusitis, AWMF-Register-Nr. 017/049 und 053–012; Deutsche Gesellschaft 2017; Available from: www.hno.org (last accessed on 27 August 2025).

e33. Klug TE, Greve T, Hentze M: Complications of peritonsillar abscess. Ann Clin Microbiol Antimicrob 2020; 19: 32.

e34. Cohen SM, Kim J, Roy N, Courey M: Factors influencing referral of patients with voice disorders from primary care to otolaryngology. Laryngoscope 2014; 124: 214–20.

e35. Bernstein JA, Cremonesi P, Hoffmann TK, Hollingsworth J: Angioedema in the emergency department: A practical guide to differential diagnosis and management. Int J Emerg Med 2017; 10: 15.

e36. Plontke SK, Girndt M, Meisner C, et al.: High-dose glucocorticoids for the treatment of sudden hearing loss. NEJM Evid 2024; 3: EVIDoa2300172.

e37. Braun EM, Tomazic PV, Ropposch T, Nemetz U, Lackner A, Walch C: Misdiagnosis of acute peripheral vestibulopathy in central nervous ischemic infarction. Otol Neurotol 2011; 32: 1518–21.

e38. Bressler K, Shelton C: Ear foreign-body removal: A review of 98 consecutive cases. Laryngoscope 1993; 103: 367–70.

e39. Zalzal HG, Ryan M, Reilly B, Mudd P: Managing the destructive foreign body: Water beads in the ear (a case series) and literature review. Ann Otol Rhinol Laryngol 2023; 132: 1090–5.

e40. Oreh AC, Folorunsho D, Ibekwe TS: Actualities of management of aural, nasal, and throat foreign bodies. Ann Med Health Sci Res 2015; 5: 108–14.

e41. Lee JH, Lee JS, Kim DK, Park CH, Lee HR: Clinical outcomes of silk patch in acute tympanic membrane perforation. Clin Exp Otorhinolaryngol 2015; 8: 117–22.

e42. Nanu DP, Adelsberg D, Nguyen SA, Radulovich NP, Carr MM: Unmasking nasal septal hematoma/abscess: A systematic review and meta-analysis. OTO Open 2024; 8: e174.